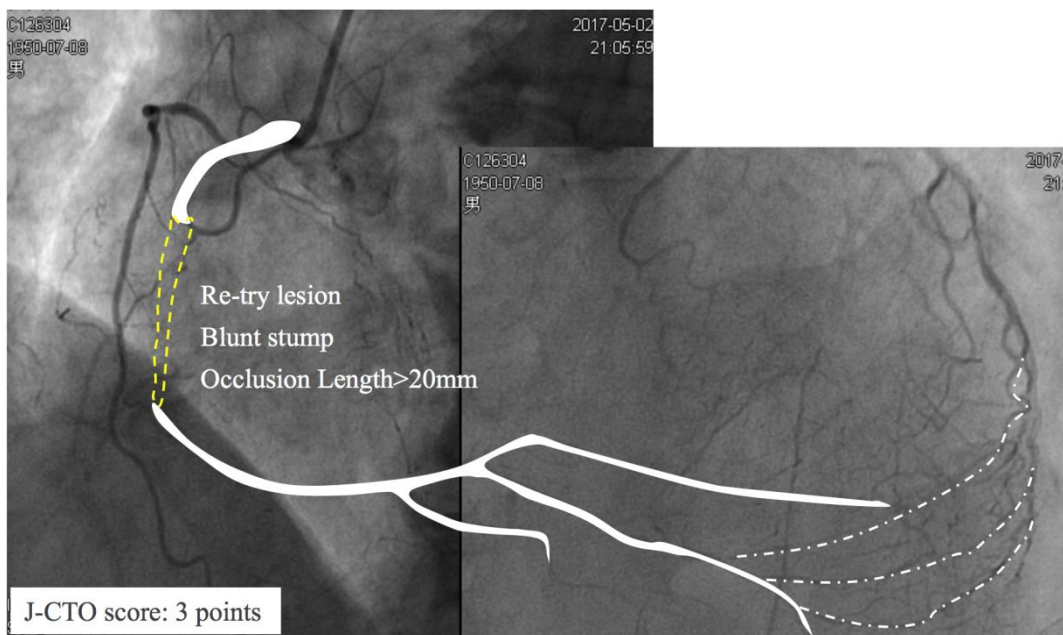
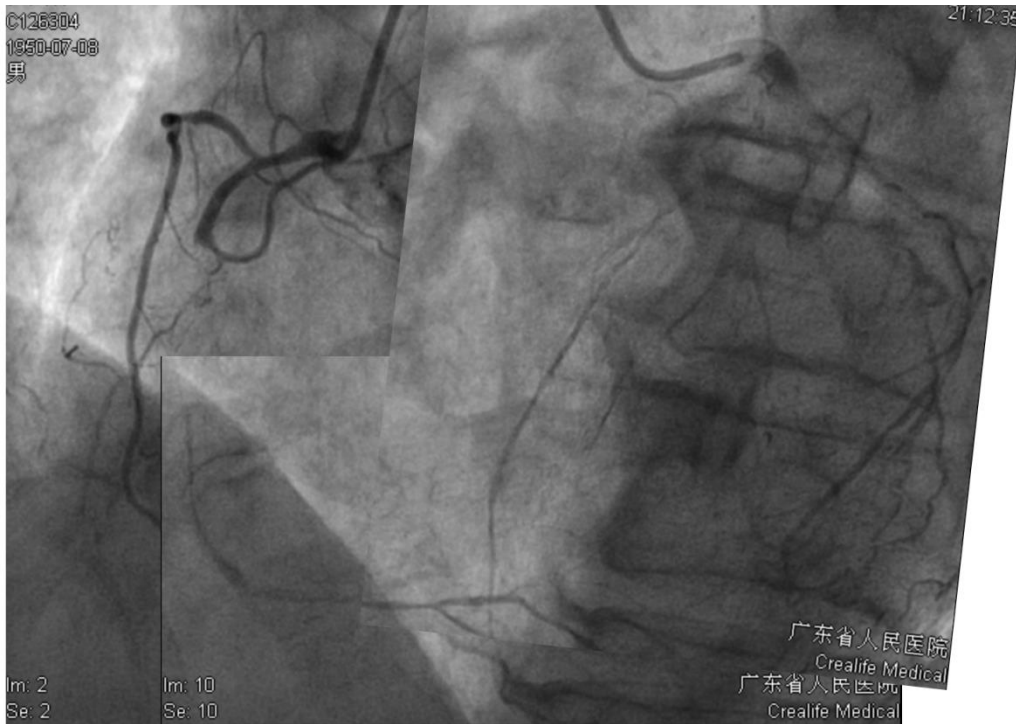

CASE 02

- Male, 66y, angina for 3 years, aggravate for 6 months
- HTN (-), DM (+), smoker, LVEF: None
- CAG: LAD(CTO), LCX70%, **Target vessel RCA(CTO)**



Strategy

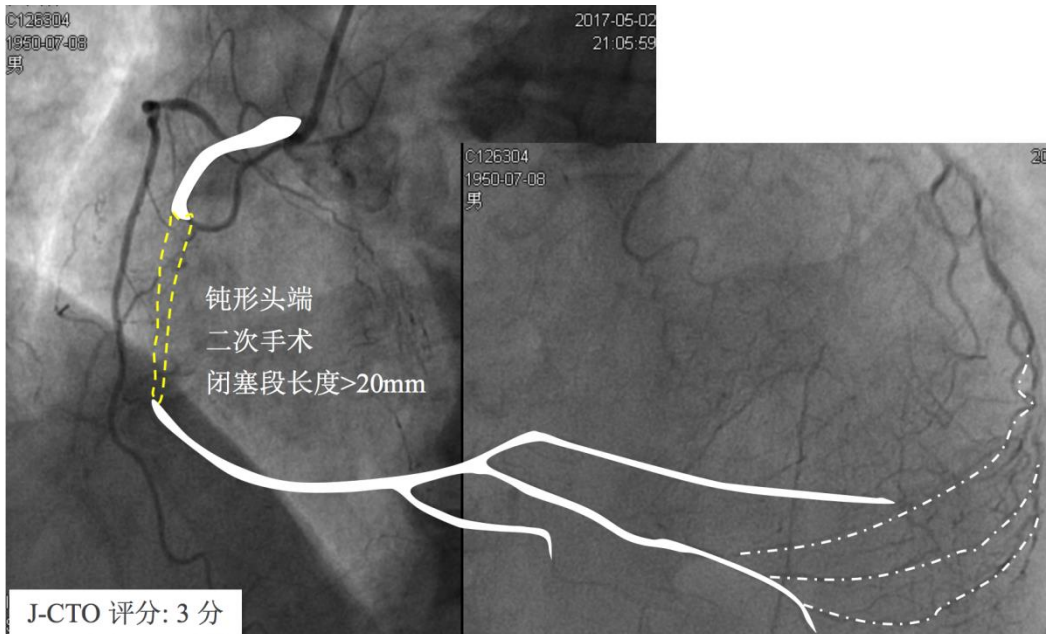
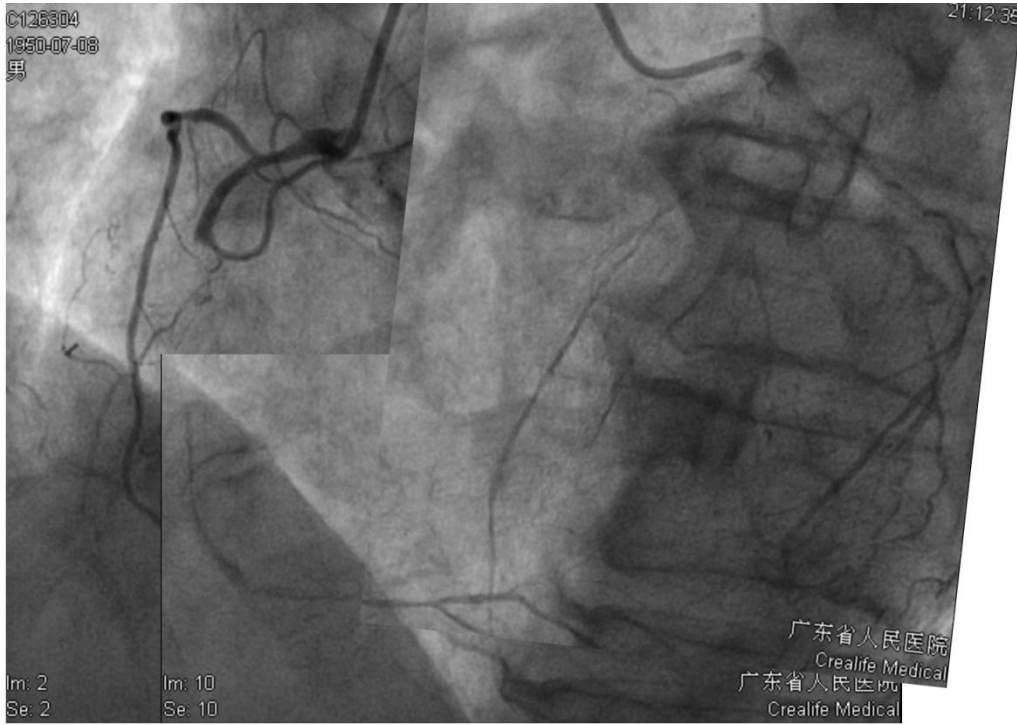Equipment

Collateral Channels

CTO Technology

CASE 02

- 男性, 66 岁, 胸痛 3 年, 加重 6 个月
- 高血压(-), 糖尿病(+), 吸烟, LVEF: 无
- 冠脉造影结果: LAD(CTO), LCX70%, 目标血管 **RCA(CTO)**



介入策略

器械

侧支循环选择

技术