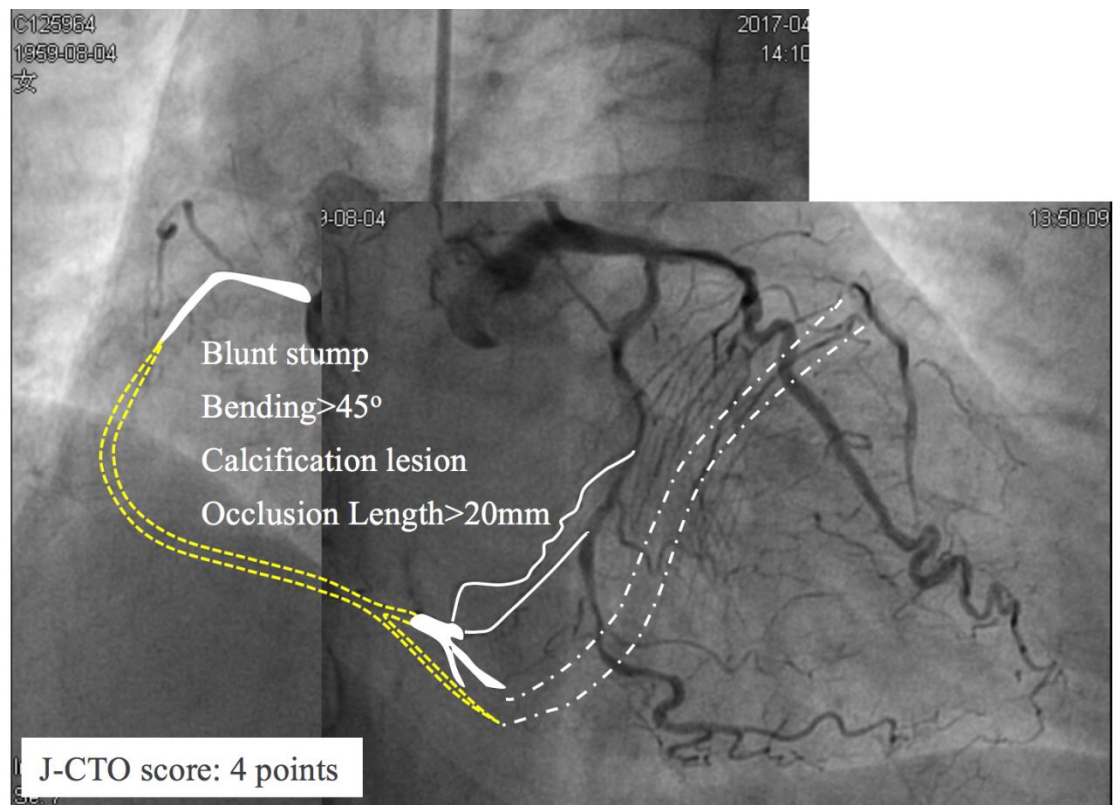
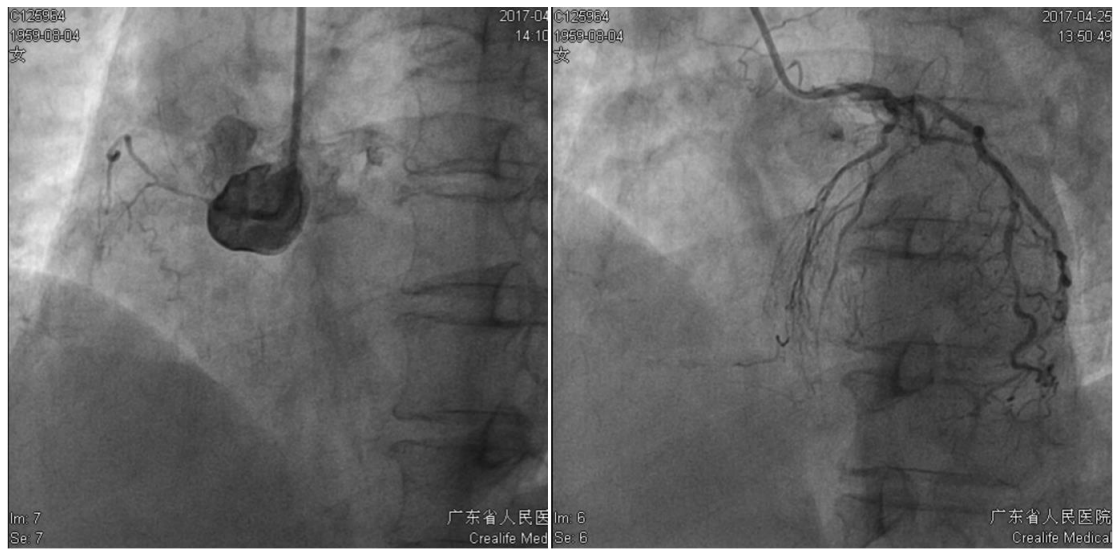


## CASE 03

- Female, 57y, angina for 7 years, aggravate for 1 week
- HTN (+), DM (+). LVEF: 42%
- CAG: LAD (CTO,2017/4/25 PCI), LCX60-70%, **Target vessel RCA(CTO)**



### Strategy

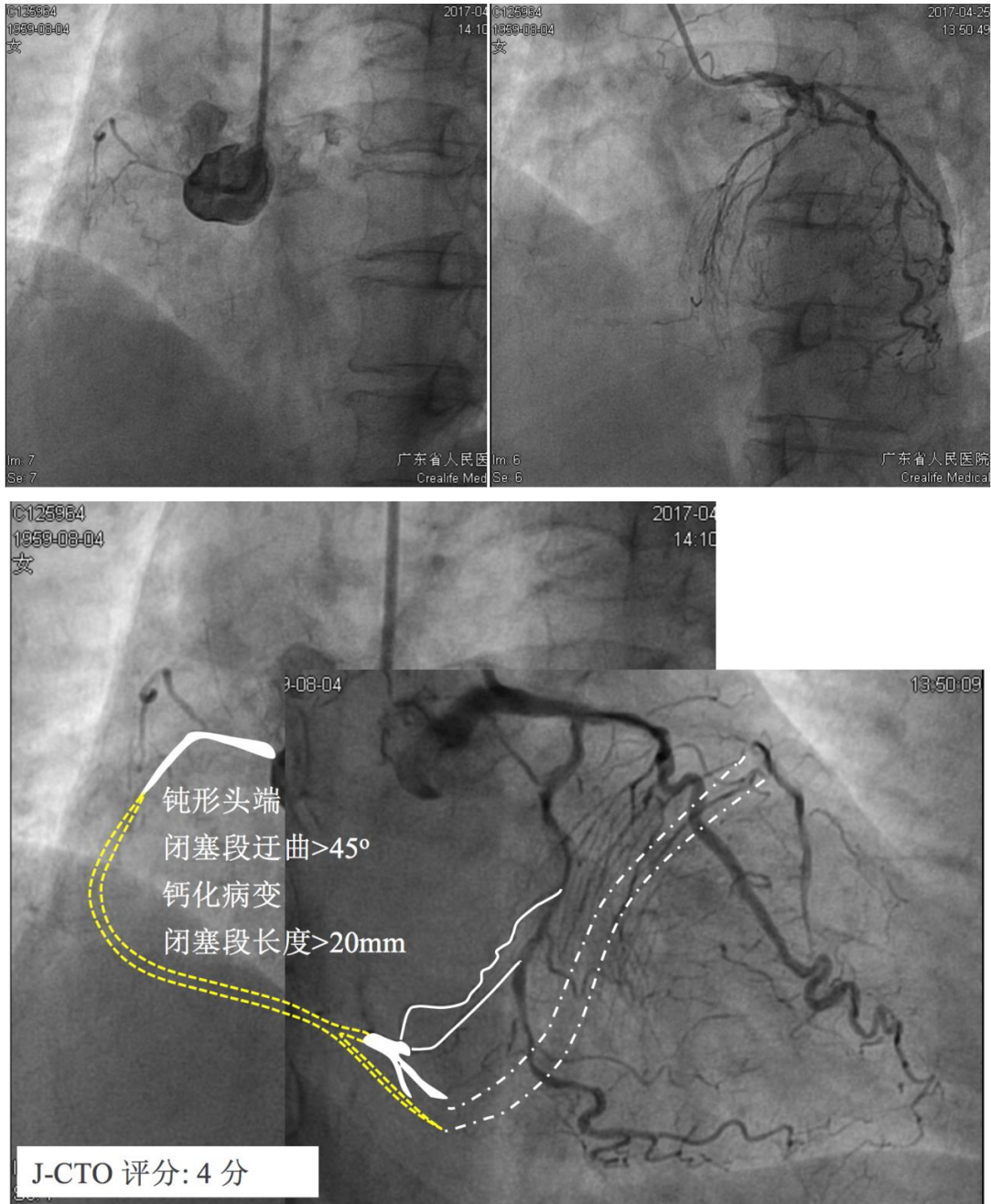
Equipment

Collateral Channels

CTO Technology

## CASE 03

- 女性, 57 岁, 胸痛 7 年, 加重 1 周
- 高血压(+), 糖尿病(+), LVEF:42%
- 冠脉造影结果: LAD(CTO,2017/4/25 PCI), LCX60-70%, 目标血管 **RCA(CTO)**



### 介入策略

器械

侧支循环选择

技术