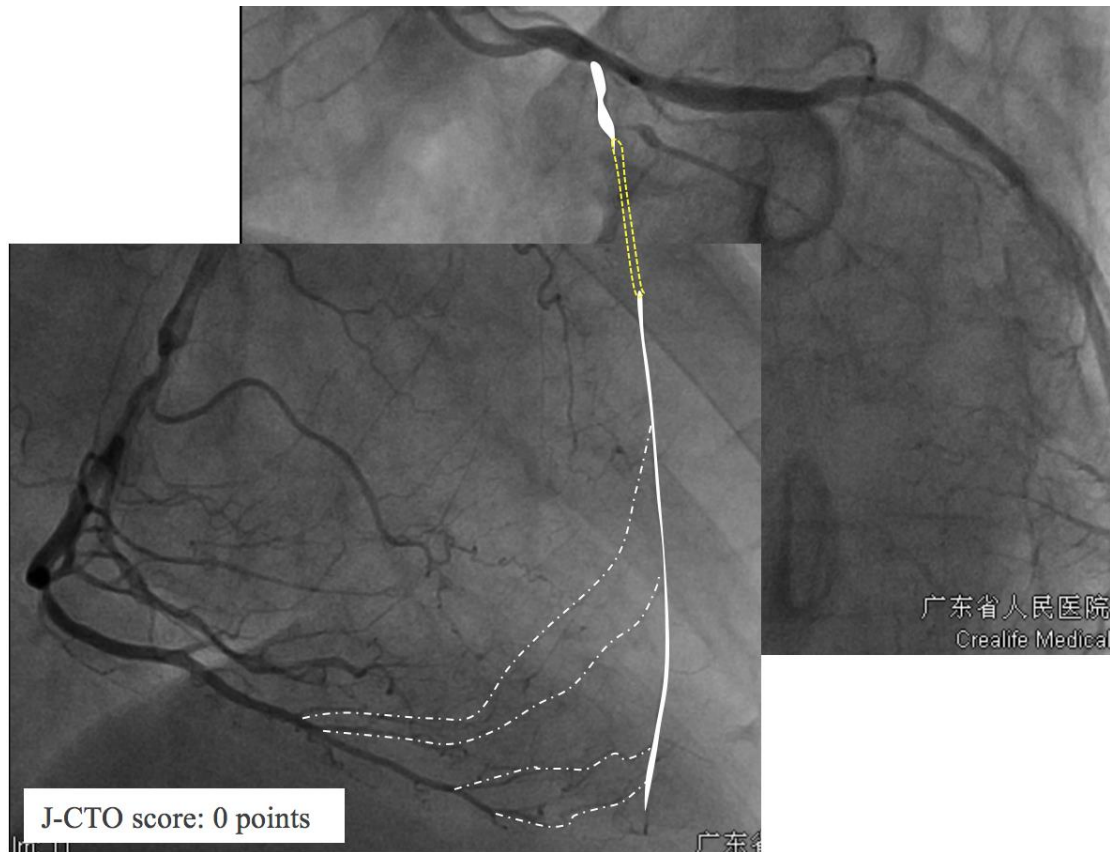
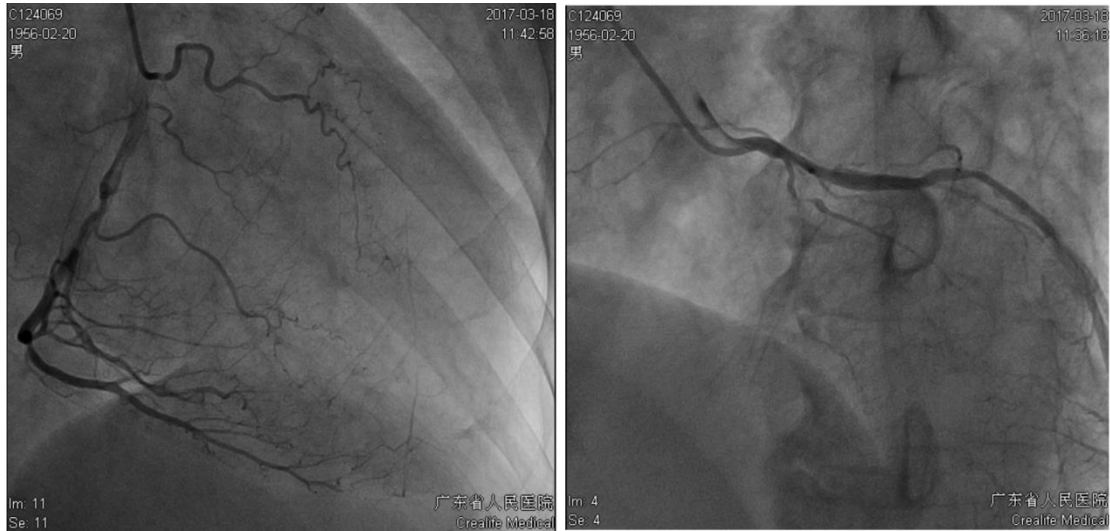


## CASE 04

- Male, 61y, angina for 1 months
- HTN (-), DM (+). LVEF: 39%
- CAG: RCA 50-60%, LCX 50%, **Target vessel LAD(CTO)**



### Strategy

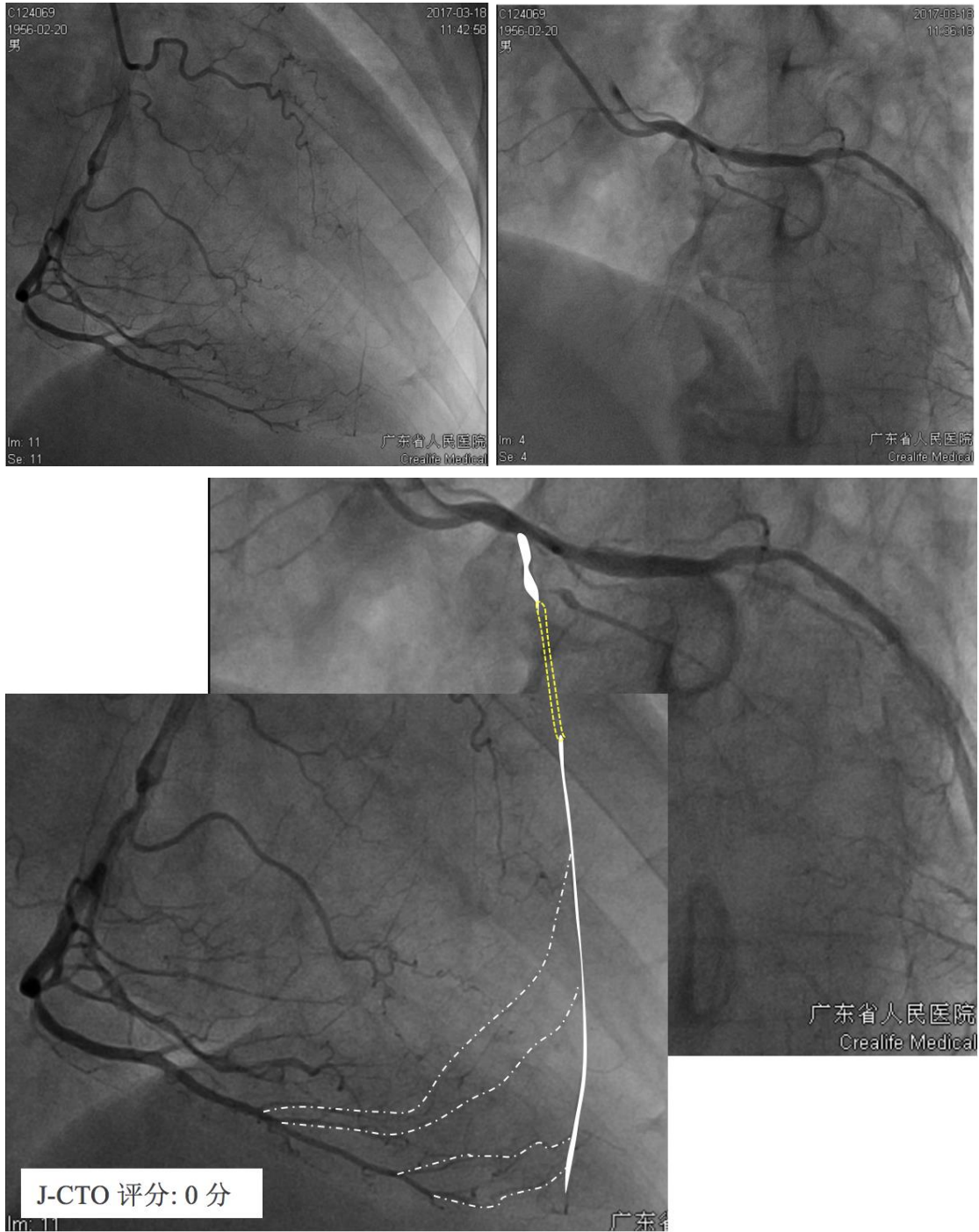
Equipment

Collateral Channels

CTO Technology

## CASE 04

- 男性, 61 岁, 胸痛 1 月
- 高血压(+), 糖尿病(+), LVEF: 39%
- 冠脉造影结果: RCA 50-60%, LCX 50%, 目标血管 LAD(CTO)



### 介入策略

器械

侧支循环选择

技术