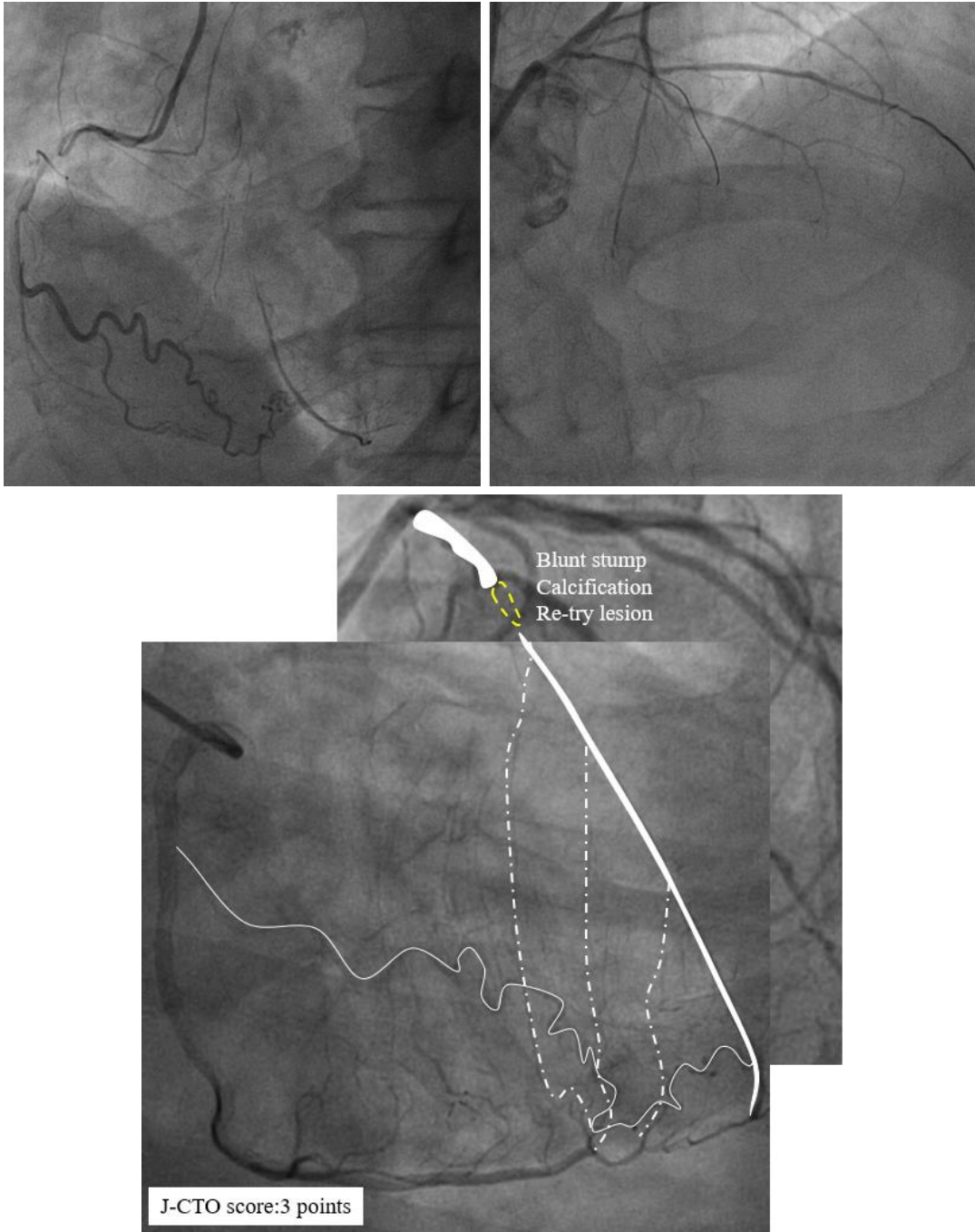


CASE 07

- Male, 69y, angina for 4 months
- HTN (-), DM (-), LVEF:40%
- CAG: RCA (CTO,2017/01/24 PCI), LM (60-70%,2017/03-28 PCI), **Target vessel LAD(CTO)**



Strategy

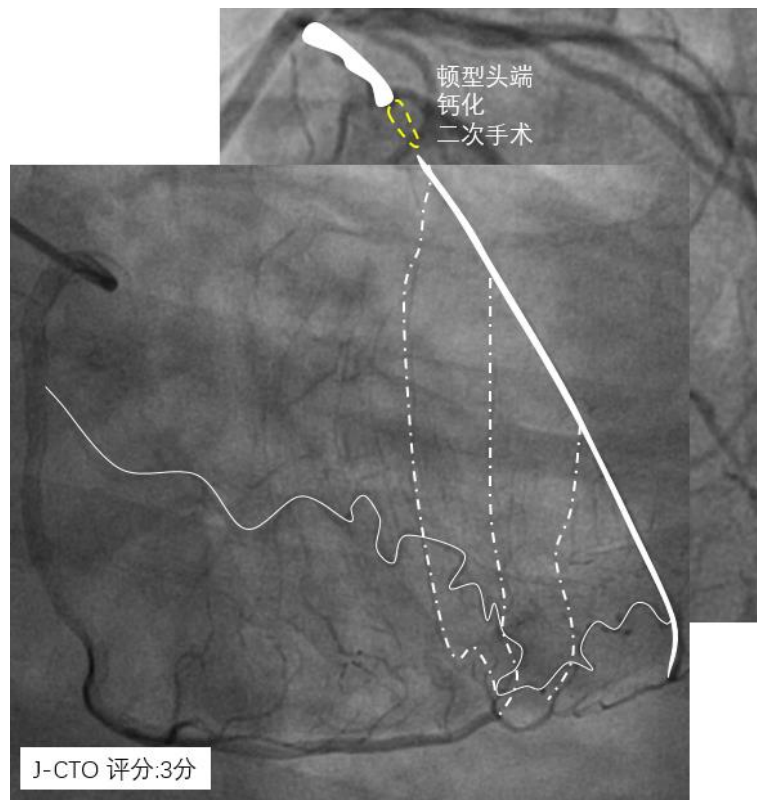
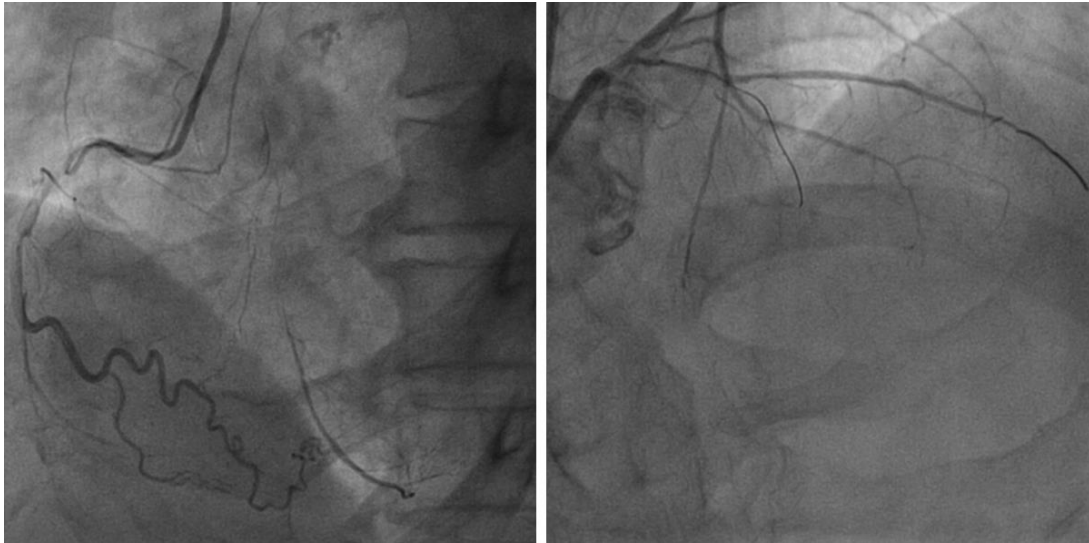Equipment

Collateral Channels

CTO Technology

CASE 07

- 男性, 69y, 胸痛 4 月余
- 高血压(-), 糖尿病(-), LVEF: 40%
- 冠脉造影: RCA(CTO, 2017/01/24 PCI), LM(60-70%, 2017/03-28 PCI), 目标血管 **LAD(CTO)**



介入策略

器械

侧支循环选择

技术