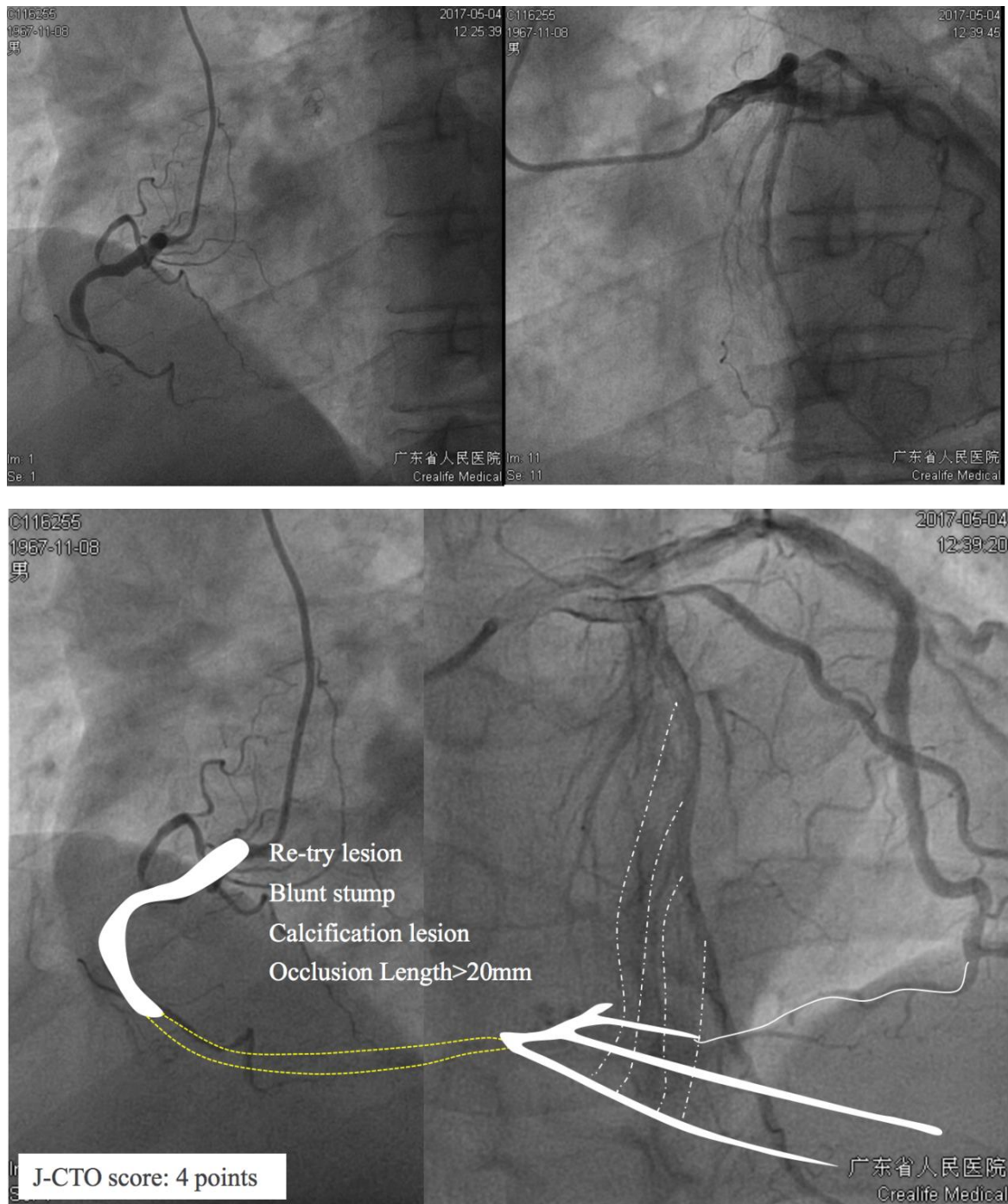


CASE 09

- Male, 61y, angina for 8 months
- HTN (-), DM (+). LVEF: 34%
- CAG: LAD (CTO,2017/5/4 PCI), LCX40%, **Target vessel RCA(CTO)**



Strategy

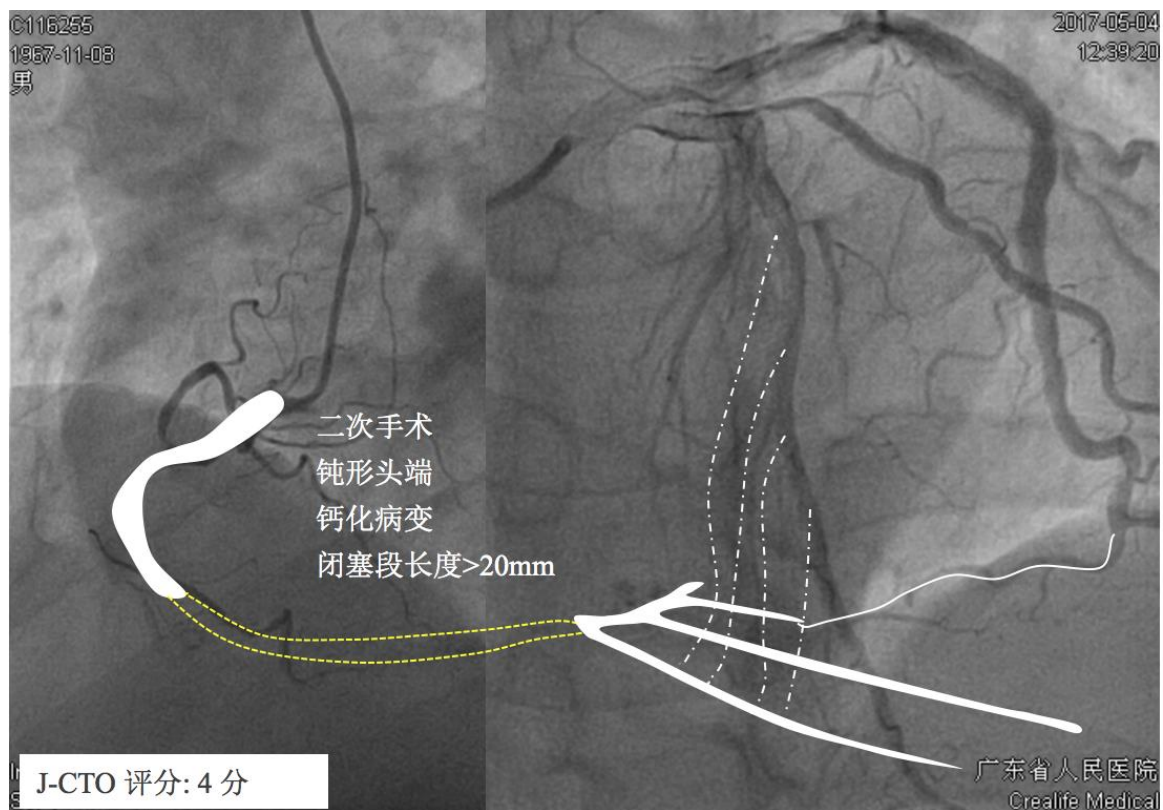
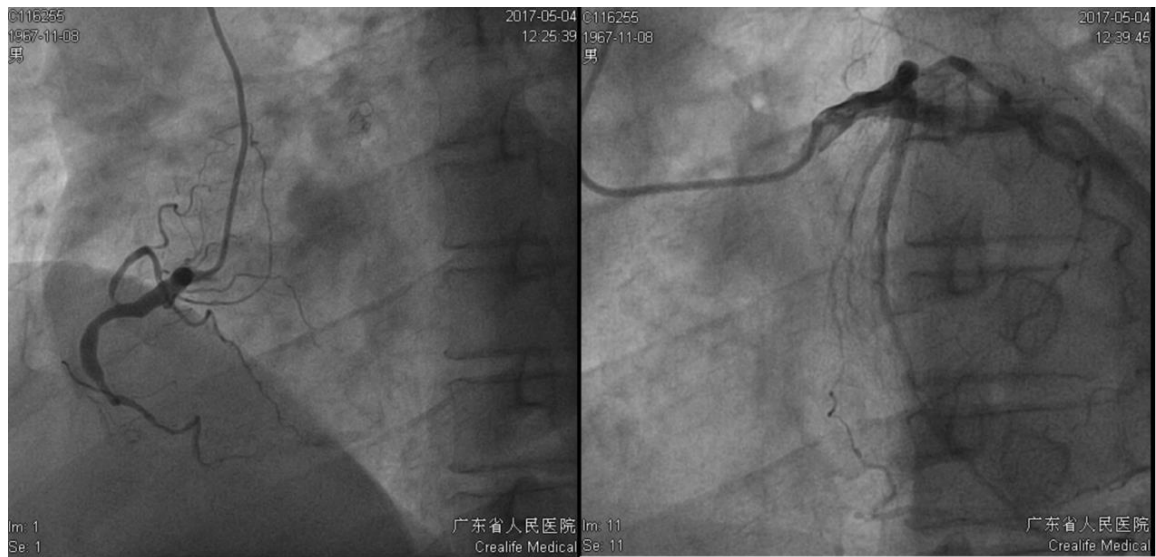
Equipment

Collateral Channels

CTO Technology

CASE 09

- 男性, 61 岁, 胸痛 8 月
- 高血压(+), 糖尿病(+), LVEF: 34%
- 冠脉造影结果: LAD CTO(2017/5/4 PCI), LCX40%, 目标血管 **RCA(CTO)**



介入策略

器械

侧支循环选择

技术