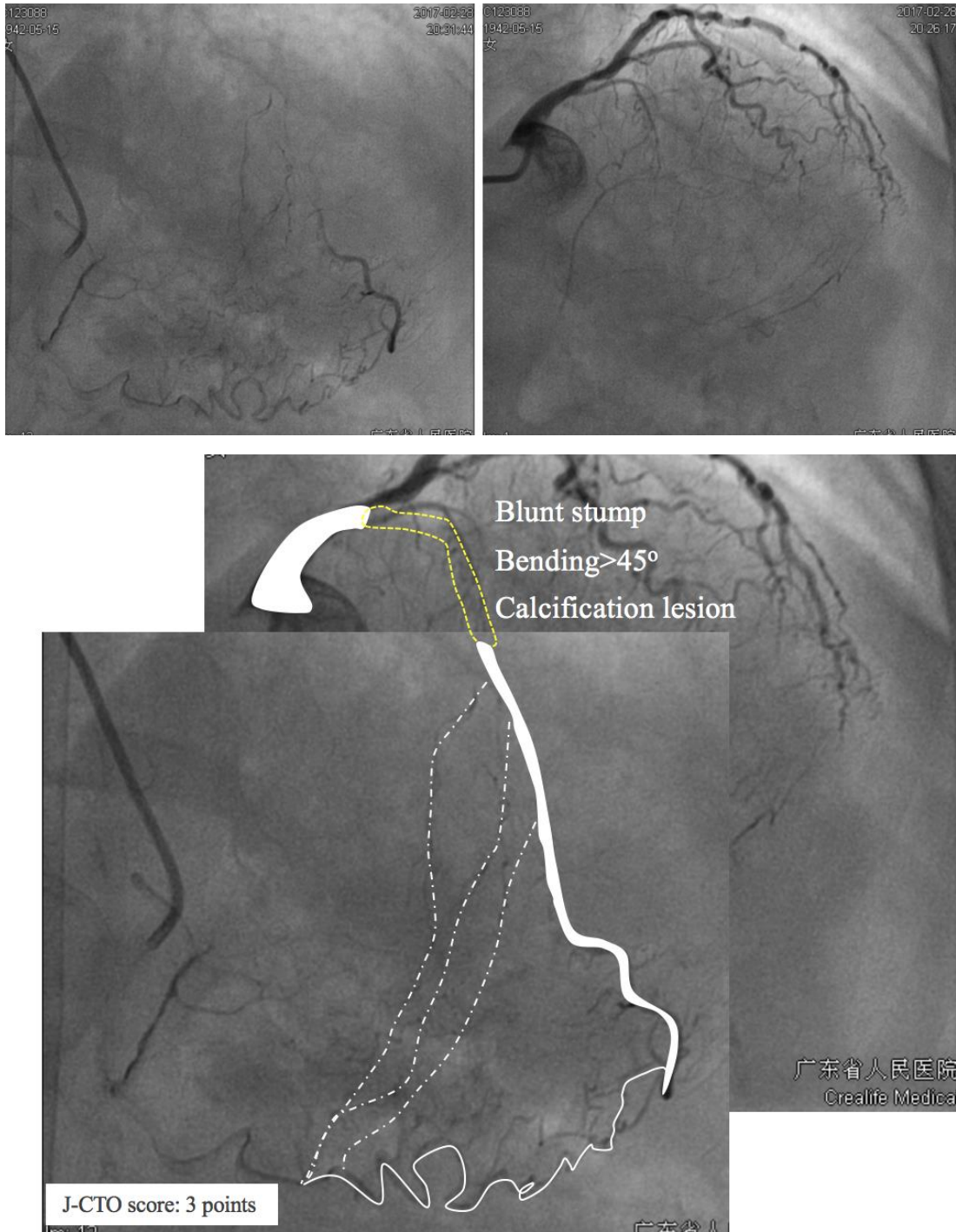


CASE 10

- Female, 75y, angina for 1 year aggravate for 2 months
- HTN (+), DM (-), LVEF: 60%
- CAG: RCA (CTO,2017/2/28 PCI), LCX 60-70%, Target vessel LAD(CTO)



Strategy

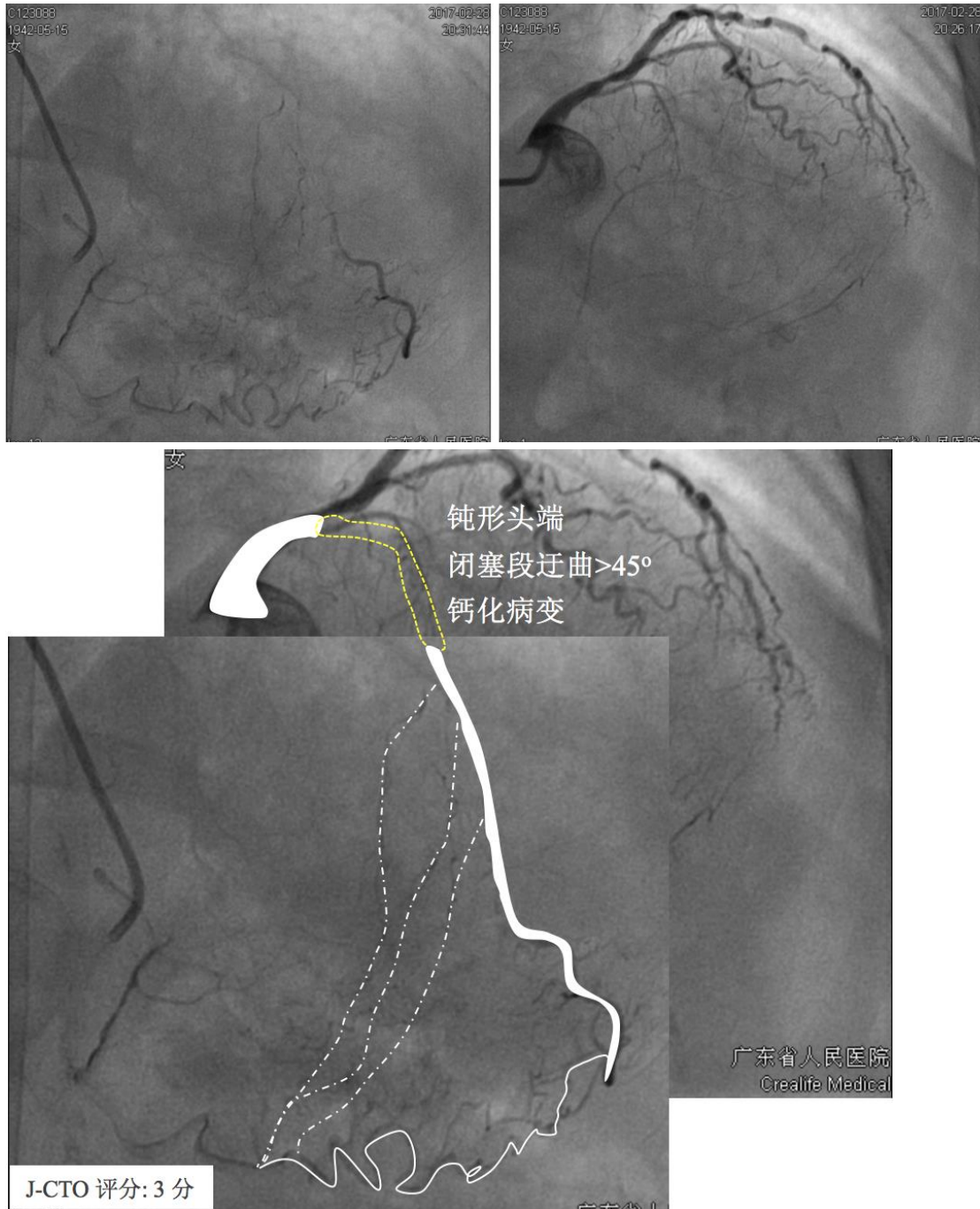
Equipment

Collateral Channel

CTO Technology

CASE 10

- 女性, 75 岁, 胸痛 1 年, 加重 2 月
- 高血压(+), 糖尿病(-), LVEF: 60%
- 冠脉造影结果: RCA (CTO, 2017/2/28 PCI), LCX 60-70%, 目标血管 **LAD(CTO)**



介入策略

器械

侧支循环选择

技术