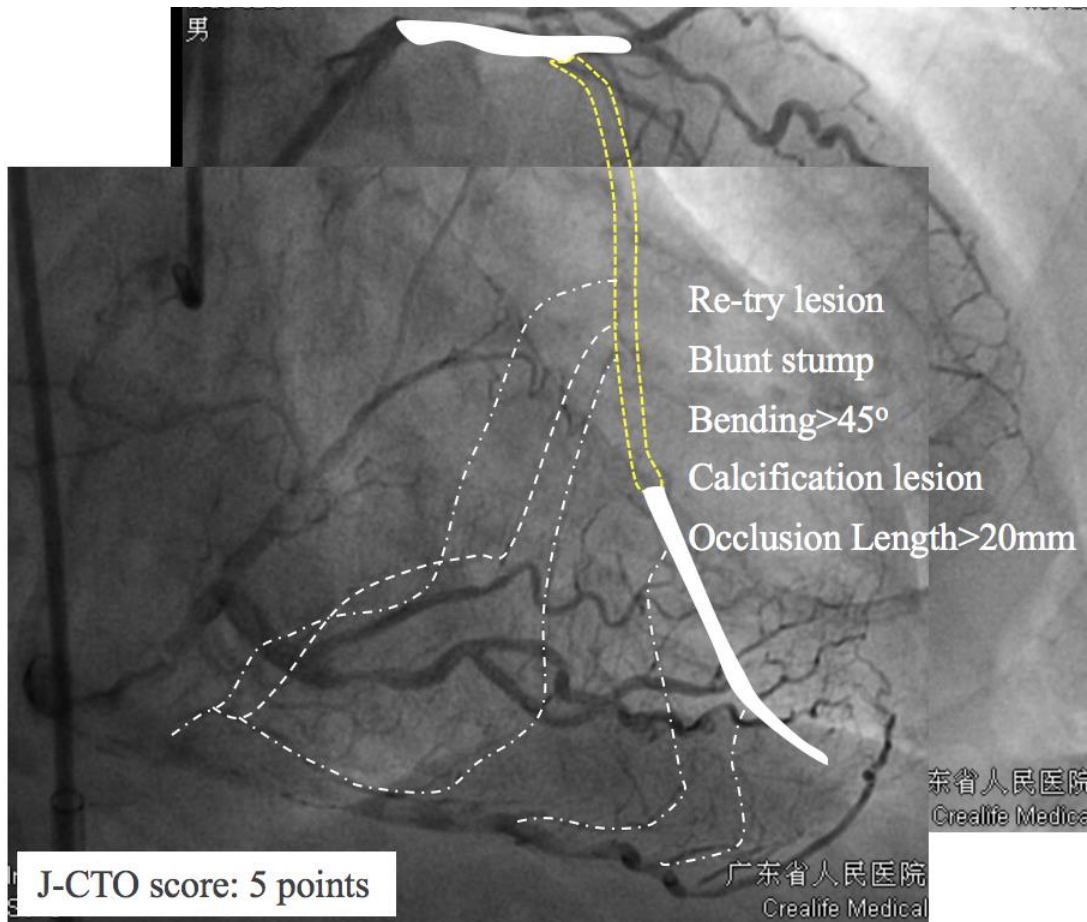
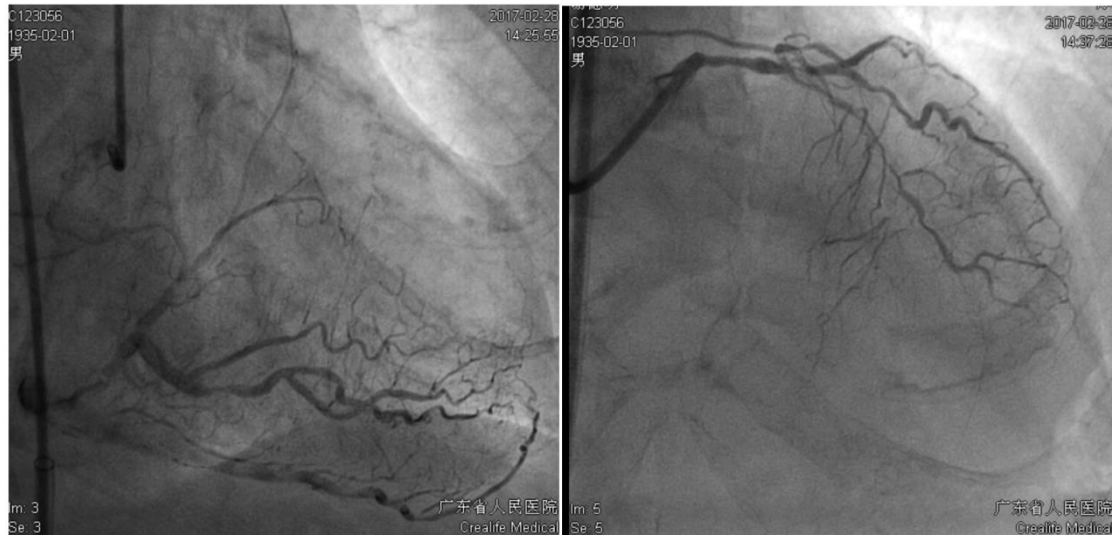

## CASE 11

- Male, 82y, angina for 1 year
- HTN (-), DM (-). LVEF: 62%
- CAG: RCA (80%,2017/2/28 PCI), LCX (CTO), Target vessel LAD(CTO)



### Strategy

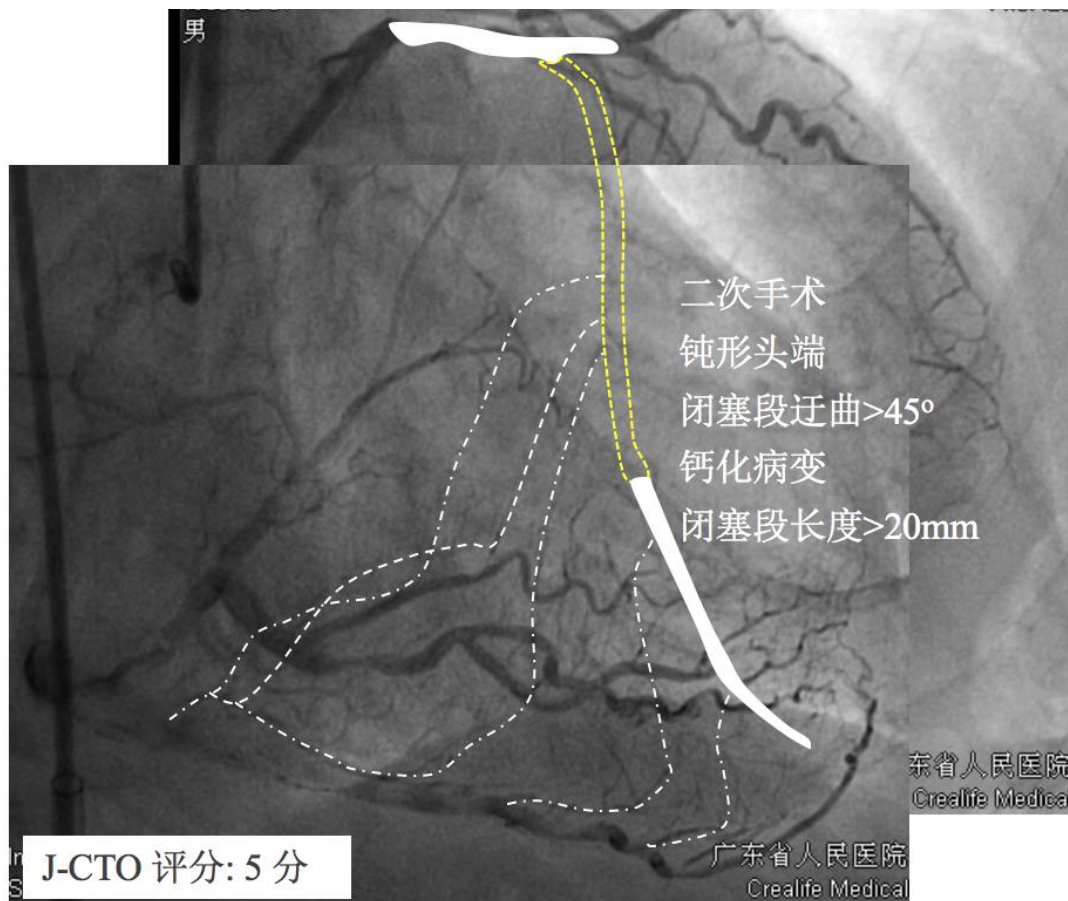
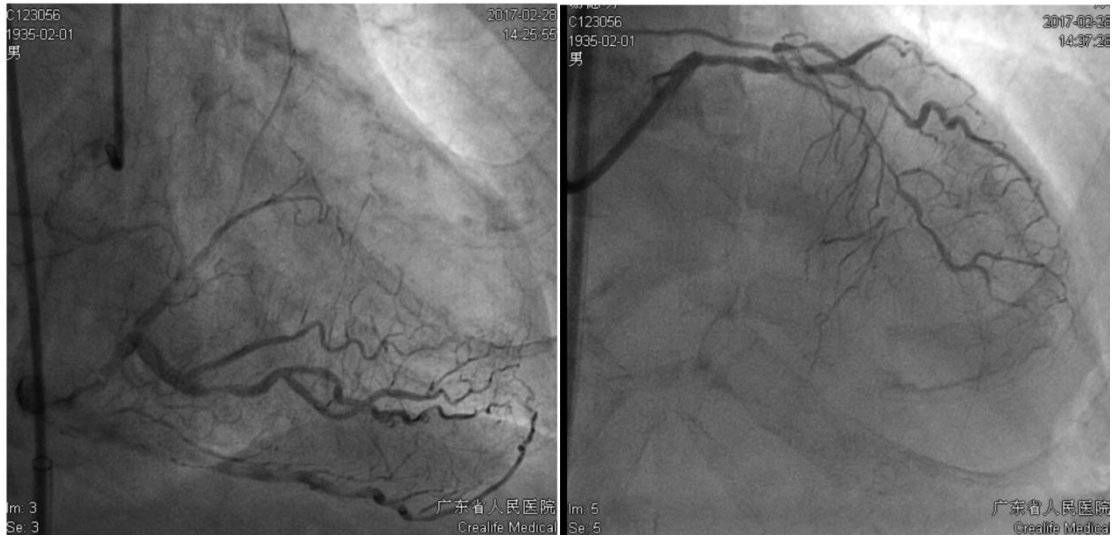
Equipment

Collateral Channel

CTO Technology

## CASE 11

- 男性,82岁,胸痛1年
- 高血压(-),糖尿病(-), LVEF:62%
- 冠脉造影结果: RCA (80%,2017/2/28 PCI), LCX (CTO), 目标血管 **LAD(CTO)**



### 介入策略

器械

侧支循环选择

技术