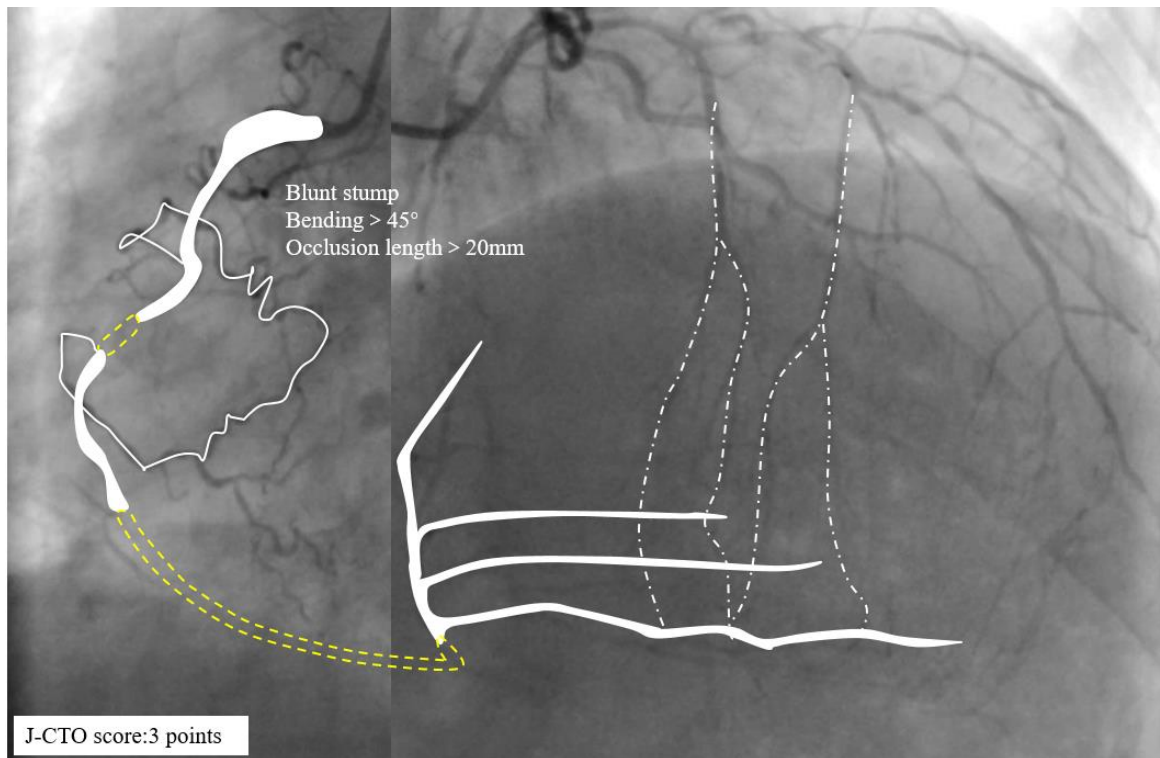
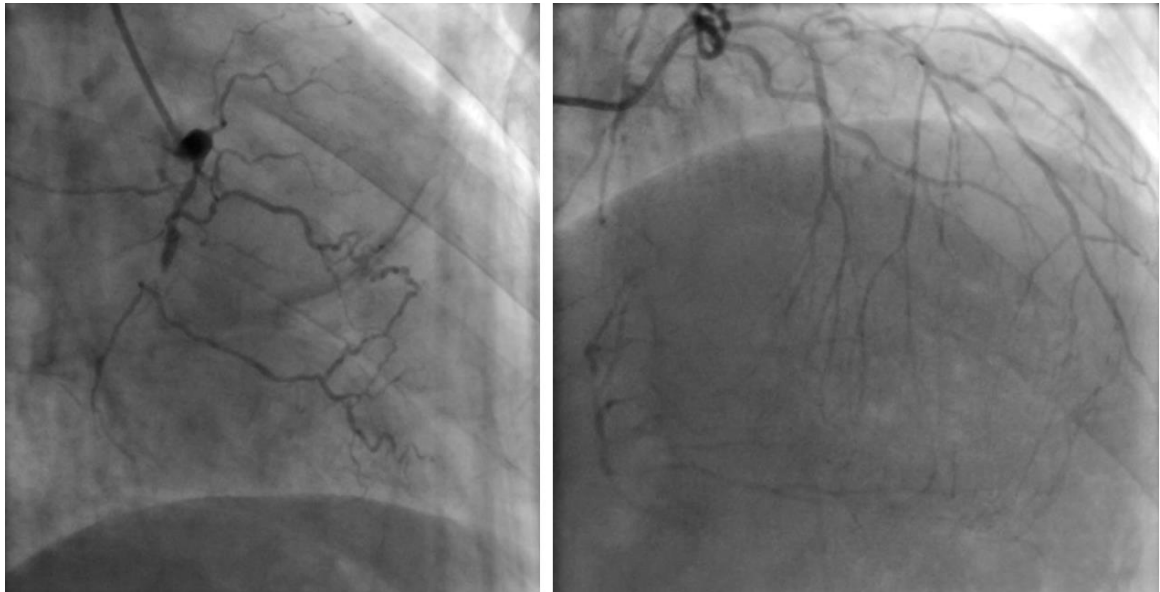

CASE 12

- Male, 46y, angina for 2 years
- HTN (+), DM (+), LVEF: None
- CAG: LAD90%, LCX70%, **Target vessel RCA(CTO)**



Strategy

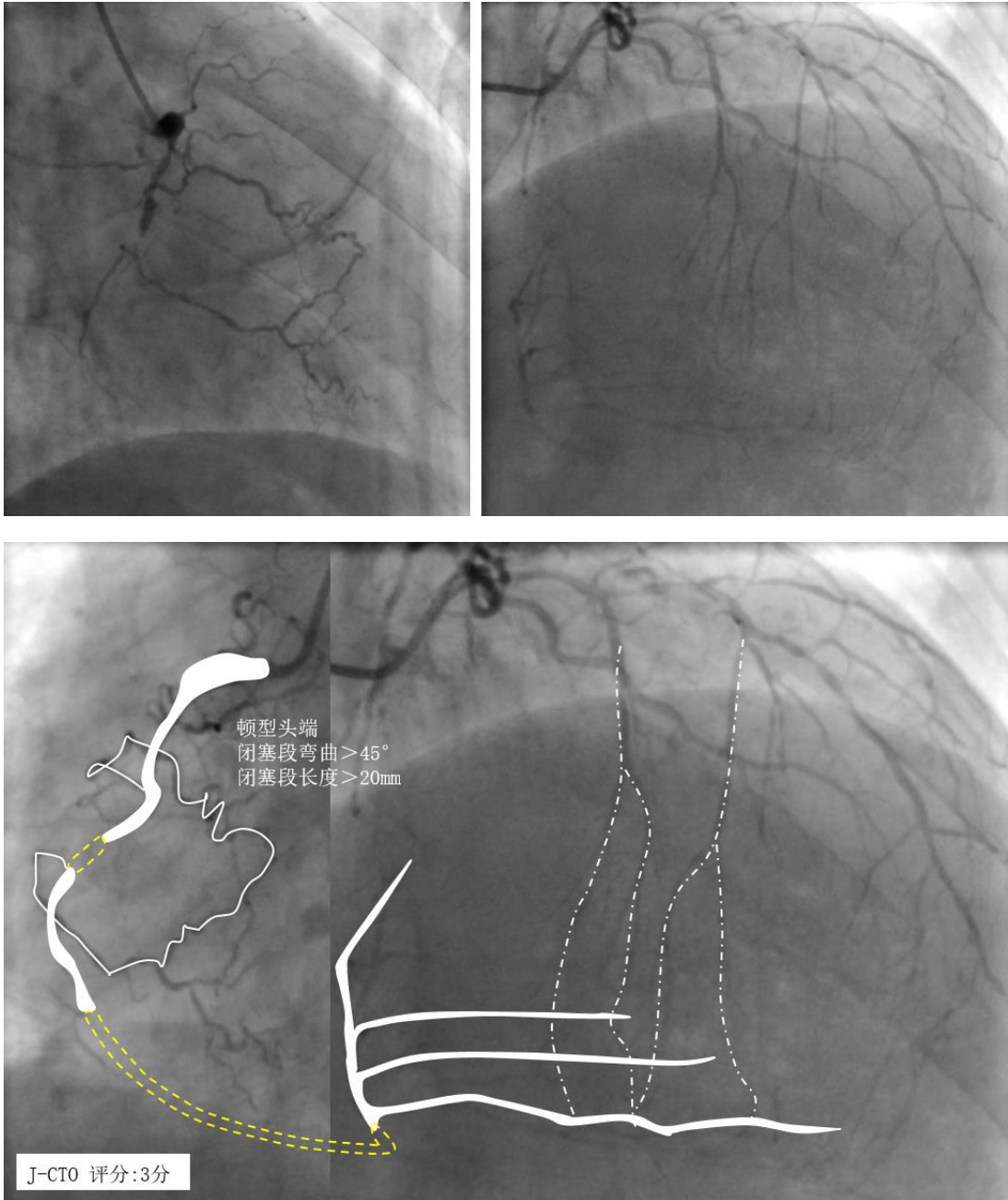
Equipment

Collateral Channels

CTO Technology

CASE 12

- 男性，46岁，胸痛2年余
- 高血压(+) 糖尿病(+), LVEF:无
- 冠脉造影: LAD90%, LCX70%, 目标血管 **RCA(CTO)**



介入策略

器械

侧支循环选择

技术